

# RECORDING OF OPHTHAMOLOGICAL FEATURES IN SUSPECTED PAEDIATRIC HEAD TRAUMA

<b>HISTORY</b> _____ Continue on reverse

PATIENTS DETAILS
------------------

<b>Visual Acuity</b>	<b>Right eye</b>	<b>Left eye</b>
----------------------	------------------	-----------------

If possible to assess

### OCULAR MOTILITY

<input type="checkbox"/>	⤴	<input type="checkbox"/>	<input type="checkbox"/>	⤵	<input type="checkbox"/>
<input type="checkbox"/>	Right eye	<input type="checkbox"/>	<input type="checkbox"/>	Left eye	<input type="checkbox"/>
<input type="checkbox"/>	⤵	<input type="checkbox"/>	<input type="checkbox"/>	⤴	<input type="checkbox"/>


### SUBCONJUNCTIVAL HAEMORRHAGES

<b>Right eye</b>		<b>Left eye</b>	
Yes	No	Yes	No

### ANTERIOR SEGMENT

<b>Right Eye</b>	<b>Left Eye</b>
------------------	-----------------

<b>Pupil size and Pupillary reflexes</b>

<b>PERIOCULAR BRUISING:</b> (mark areas of bruising)


<b>Pupils dilated with</b>

<b>FUNDUS</b> <small>Circle if present</small>	<b>RIGHT EYE</b>				<b>LEFT EYE</b>			
<b>Retinal Haemorrhages</b>	YES		NO		YES		NO	
<b>NUMBER</b> of Retinal haemorrhage	Few (1-10)	Many(10-20)	Too numerous to count		Few (1-10)	Many(10-20)	Too numerous to count	
<b>LOCATION</b> of retinal haemorrhages	Pre retinal	Intraretinal	Subretinal	Multilayered	Pre retinal	Intraretinal	Subretinal	Multilayered
<b>DISTRIBUTION</b> of retinal haemorrhages	Posterior Pole Few/many/ too numerous to count (Zone 1- ROP classification)		Periphery Few/many/ too numerous to count (outside Zone1)		Posterior Pole Few/many/ too numerous to count (Zone 1- ROP classification)		Periphery Few/many/ too numerous to count (outside Zone1)	
<b>SIZE</b> of retinal haemorrhages	Small (< 1dd)	Medium 1-2dd	Large >2dd		Small (< 1dd)	Medium 1-2dd	Large >2dd	
<b>MORPHOLOGY</b> of haemorrhages White centered or other								
<b>Macula Retinoschisis</b>								
<b>Perimacular folds</b>								
<b>Optic disc</b>								
<b>OTHER</b> findings								

Circle single or multiple appropriate responses if present or enter free text

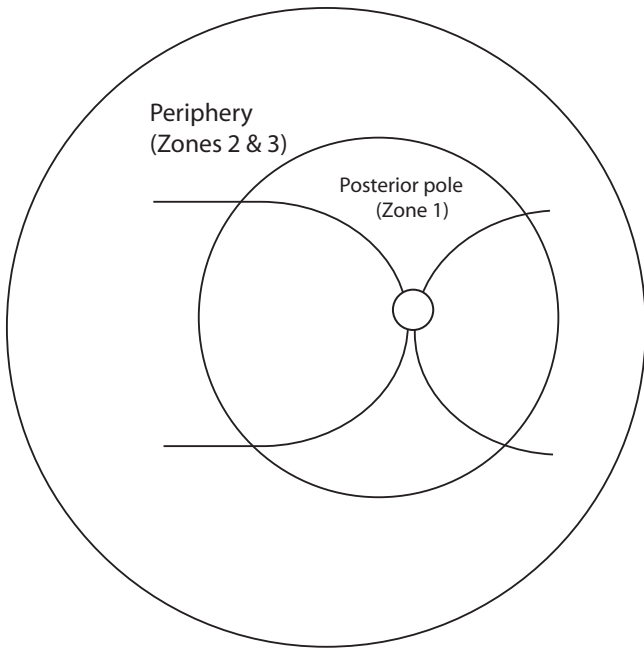
<b>Name and signature</b>
<b>Date and time</b> of examination

**Fundus examined with**  
 Indirect ophthalmoscope (and 20d / 28d / 30d / 2.2d)  
 Retcam  OR Photography   
 OCT

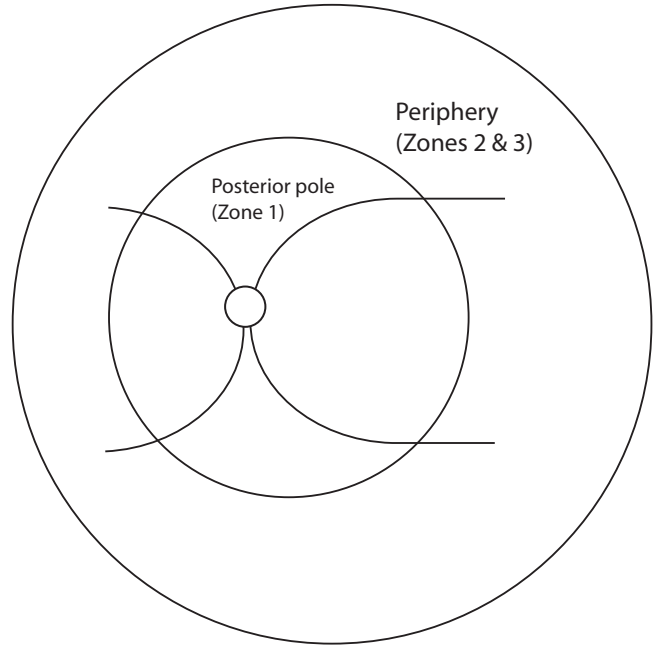
History (cont.)

Other findings

R



L



Comments

Name

Signature